

Course No: DNTS 1306
Course Title: General Anatomy
Date: 23 /3/2013
No. of Questions: (6)
Time: 1hour
Using Calculator (No)

University of Palestine



Mid-term Exam
2nd 2012/2013
Total Grade: 20

Instructor Name: Dr. Amjad El-Shanti
Student No.: _____
Student Name: _____
College Name: Faculty of Dentist and Oral surgery
Dep. / Specialist: _____
Using Dictionary (No)

Question One: Put the sign (✓) against the right sentences and the sign (X) against the wrong sentences: (2.5 Marks).

1. Gomphosis binds teeth to bony sockets in the maxilla and mandible ().
2. The mid- saggital plane divides the body or organs into superior and inferior ().
3. Squamous suture separates the parietal bone from the temporal bone ().
4. Cytology is a macroscopic study of the structure of cells ().
5. The pericardial cavity surrounds the lungs. ().
6. Injury of radial nerve leads to Ape hand ().
7. Articular Cartilages resemble fibrous cartilages in other areas of the body().
8. Carpal and Tarsal bones are example of irregular bones ().
9. Zygomaticus major muscle draws angle of mouth upward and outward and innervated by facial nerve ().
10. Anterior interosseous nerve is a branch of the median nerve, while posterior interosseous nerve is a branch of the radial nerve ().

Question Two: Write the scientific term against the following phrases: (1.25 Marks).

1. () Position where the body is lying face down.
2. () Types of nervous tissue cells do not transmit impulses, but support neurons.
3. () a broad, median partition between the lungs that extends from the sternum to the vertebral column.
4. () Type of connective tissue cells responsible for production of the fibers.
5. () Ribs that joint the sternum directly.

Question Three: Select and circle the correct answer from the following alternatives for each sentence: (5 Marks).

1. Regarding the articulations of the clavicle, one is correct:

- a. The medial end articulates with the manubrium by fibrous articulation.
- b. The medial end articulates with the manubrium by cartilaginous articulation.
- c. The medial end articulates with the body of the sternum by saddle synovial joint.
- d. The lateral end articulates with the acromion by fibrous articulation.
- e. The lateral end articulates with the acromion by plane synovial articulation.

2. One of the following is not attached to the medial border of the scapula:

- a. Levator scapulae.
- b. Teres minor.
- c. Serratus anterior.
- d. Rhombideus minor.
- e. Rhomboideus major.

3. The glenoid cavity articulates with the head of the humerus by a:

- a. Fibrous articulation.
- b. Cartilaginous articulation.
- c. Plane synovial articulation.
- d. Ball and socket synovial articulation.
- e. Hinge synovial articulation

Course No: DNTS 1306
Course Title: General Anatomy
Date: 23 /3/2013
No. of Questions: (6)
Time: 1hour
Using Calculator (No)

University of Palestine



Mid-term Exam
2nd 2012/2013
Total Grade: 20

Instructor Name: Dr. Amjad El-Shanti
Student No.: _____
Student Name: _____
College Name: Faculty of Dentist and Oral surgery
Dep. / Specialist: _____
Using Dictionary (No)

4. The bicipital (Intertubercular) groove of the humerus lodges (contains) the:

- a. Axillary artery.
- b. Long head of the biceps.
- c. Long head of the triceps.
- d. Coracobrachialis.
- e. None of the above.

5. Muscle/s taking origin from the clavicle is/are:

- a. Subclavius.
- b. Trapezius.
- c. Pectoralis major.
- d. All of the above.
- e. a and b only.

6. The posterior wall of the axilla is formed by all of the following EXCEPT:

- a. Pectoralis major.
- b. Teres major.
- c. Latissimus dorsi.
- d. Subscapularis
- e. None of the above answer is correct

7. The suprascapular nerve is a branch from the:

- a. Roots of the brachial plexus.
- b. Upper trunk.
- c. Middle trunk.
- d. Posterior cord.
- e. Lateral cord.

8. The bony roof of the mouth is formed by:

- a. Palatine bones.
- b. The vomer.
- c. Maxillae.
- d. The sphenoid bone.
- e. Both a and c

9. The trapezius muscle is supplied by the:

- a. Cranial accessory nerve.
- b. Spinal accessory nerve.
- c. Long thoracic nerve.
- d. Dorsal scapular nerve.
- e. Thoracodorsal nerve.

10. One of the following muscles is not a rotator cuff muscle:

- a. Supraspinatus.
- b. Infraspinatus.
- c. Teres minor.
- d. Teres major.
- e. Subscapularis.

Course No: DNTS 1306
Course Title: General Anatomy
Date: 23 /3/2013
No. of Questions: (6)
Time: 1hour
Using Calculator (No)

University of Palestine



Mid-term Exam
2nd 2012/2013
Total Grade: 20

Instructor Name: Dr. Amjad El-Shanti
Student No.: _____
Student Name: _____
College Name: Faculty of Dentist and Oral surgery
Dep. / Specialist: _____
Using Dictionary (No)

11. Actions of the latissimus dorsi muscle:

- a. Flexes the arm.
- b. Abducts the arm.
- c. Laterally rotates the arm.
- d. All of the above.
- e. None of the above.

12. Regarding the biceps brachii, one is INCORRECT:

- a. Has long head attached to the supraglenoid tubercle.
- b. Has short head attached to the tip of the coracoid process.
- c. Has a tendon inserted into the radial tuberosity.
- d. It flexes the elbow joint.
- e. It is powerful supinator of the extended elbow.

13. which of the following layers of Epidermis not found in thin skin:

- a. Stratum corneum
- b. Stratum lucidum
- c. Stratum granulosum
- d. Stratum spinosum
- e. Stratum basale

14. Which of the following is part of the nasal septum?

- a. Vomer bone
- b. Zygomatic bone
- c. Maxillary bone
- d. Palatine bone
- e. Lacrimal bone

15. Which of the following is NOT considered an epidermal appendage:

- a. Sweat gland
- b. Hair
- c. Hypodermis
- d. Nails
- e. Sebaceous glands

16. The constriction below the greater and lesser tuberosities of the humerus is called:

- a. Anatomical neck.
- b. Surgical neck.
- c. Humeral shaft.
- d. Humeral ring.
- e. None of the above.

17. The proximal row of the carpal bones consists of all of the following EXCEPT:

- a. Scaphoid.
- b. Lunate.
- c. Trapezium.
- d. Pisiform.
- e. Triquetral.

Course No: DNTS 1306
Course Title: General Anatomy
Date: 23 /3/2013
No. of Questions: (6)
Time: 1hour
Using Calculator (No)

University of Palestine



Mid-term Exam
2nd 2012/2013
Total Grade: 20

Instructor Name: Dr. Amjad El-Shanti
Student No.: _____
Student Name: _____
College Name: Faculty of Dentist and Oral surgery
Dep. / Specialist: _____
Using Dictionary (No)

18. Regarding the ulnar nerve, all are correct EXCEPT:

- a. Is the largest branch of the medial cord of the brachial plexus.
- b. Carries fibers from C6, C7 and C8.
- c. Has no branches in the arm.
- d. It enters the hand superficial to the flexor retinaculum.
- e. Injury of the nerve causes partial claw hand.

19. The median nerve supplies all of the following muscles EXCEPT:

- a. Flexor carpi ulnaris.
- b. Flexor carpi radialis.
- c. Flexor digitorum superficialis.
- d. Palmaris longus.
- e. Pronator teres.

20. Bone cells capable of breaking down bonds are termed

- a. Osteocytes.
- b. Osteoblasts.
- c. Osteoclasts.
- d. Chondrocytes.
- e. Osteons.

Question Four: Define the following scientific terms: (1.25 Marks).

- 1. **Langer's Lines:**-----
- 2. **Meniscus:**-----
- 3. **Dendrites:**-----
- 4. **Ossification:**-----
- 5. **Inversion:**-----

Question Five: Enumerate the followings: (3.5 Marks).

1-Types of Epidermis Cells and their functions:

- a)-----
- b)-----
- c)-----
- d)-----

2- Types of Specialized Connective Tissues:

- a)-----
- b)-----
- c)-----

Course No: DNTS 1306
Course Title: General Anatomy
Date: 23 /3/2013
No. of Questions: (6)
Time: 1hour
Using Calculator (No)

University of Palestine



Mid-term Exam
2nd 2012/2013
Total Grade: 20

Instructor Name: Dr. Amjad El-Shanti
Student No.: _____
Student Name: _____
College Name: Faculty of Dentist and Oral surgery
Dep. / Specialist: _____
Using Dictionary (No)

3- Types of Neurons according to projections:

- a)-----
- b)-----
- c)-----

4- Muscle used in breathing:

- a)-----
- b)-----
- c)-----

Question six: Answer the following questions: (6.5 Marks).

1. Describe the structure of a typical vertebra? and how do you differentiate between the different types of vertebrae ?

2. Draw the Brachial plexus and determine the components of plexus and the origin of nerves which originate from it ?

Drawing:



3.1. Using the figure beside (3.1): identify the labeled part.

- Label A:-----
- Label B:-----
- Label C:-----
- Label D:-----
- Label E:-----
- Label F:-----
- Label G:-----
- Label H:-----
- Label I:-----
- Label J:-----
- Label K:-----

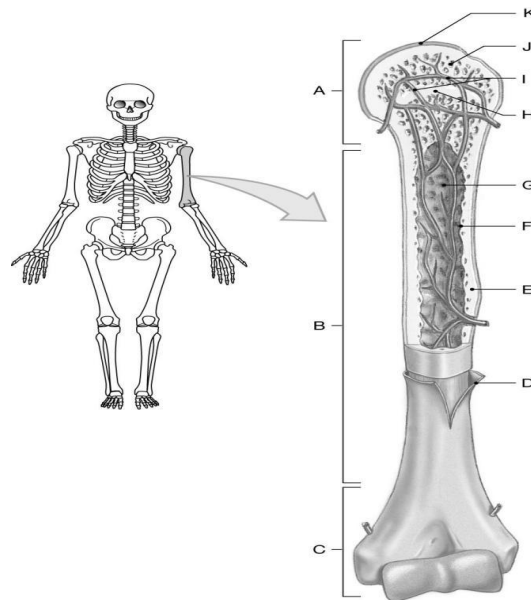


Figure 3.1

3.2. Using the figure beside (3.2):

A) What is the name of muscle?

B) Origin:-----

C) Insertion:-----

D) Action:-----

E) Nerve Supply:-----

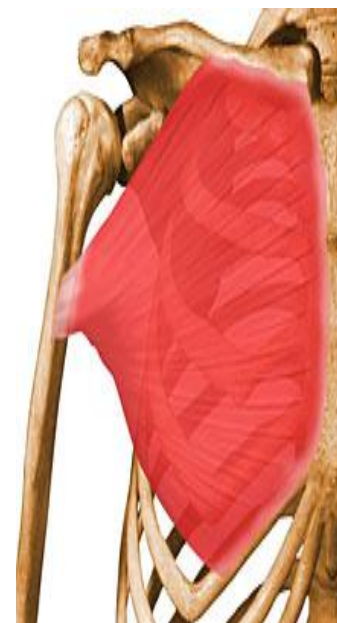

Figure 3.2

**End of Questions
 Good Luck**